



Banff Sport Medicine

BANFF SPORT MEDICINE
Orthopaedic Surgeons

207-303 Lynx Street | Box 1300 Banff AB T1L 1B3
P: 403 760 2897 F: 403 760 8234
banffsportmed.ca

Dr. Mark Heard
Dr. Greg Buchko
Dr. Laurie Hiemstra
Dr. Michaela Kopka

BSM Orthopaedic Standard X-Ray Views

1. Knee OA Series (no fracture suspected)

- Standing AP (both knees)
- Standing PA 30 degrees flexion (both knees)
- Standing Lateral 30 degrees flexion (affected knee only)
- Patella skyline view (both knees)

2. Acute Knee Series (fracture/loose body suspected)

- AP
- Medial and lateral obliques
- Cross table lateral

3. Acute Shoulder Series (fracture or dislocation suspected)

- AP
- Trans-scapular Y view
- Axillary or Velpeau view

4. Chronic Shoulder Instability Series (recurrent shoulder instability)

- True AP of glenohumeral joint
- Stryker Notch View
- West point Axillary View

5. Rotator Cuff Series (chronic shoulder pain)

- True AP of glenohumeral joint
- Zanca view of acromioclavicular joint
- Rockwood view

6. Patellar Instability Series (recurrent patellar subluxation/dislocation)

- AP
- Lateral (posterior condyles must line up)
- Patella skyline view (bilateral)
- Standing PA 30 degrees flexion (affected knee only)

7. Foot OA Series

- Weight-bearing AP
- Weight-bearing Lateral
- Non-weight-bearing oblique

8. Ankle OA Series

- Weight-bearing AP
- Weight-bearing Lateral
- Mortise

9. Hip Series

- Weight-bearing AP Pelvis including both hips
- Cross-table lateral
- Frog-leg lateral (for femoroacetabular impingement only))

10. Hand

- AP, Lateral, & Oblique

11. Wrist

- AP, Lateral, & Oblique

12. Elbow

- AP, Lateral, & internal and external oblique views

13. L-Spine

- AP, Lateral, L5/S1 spot if required

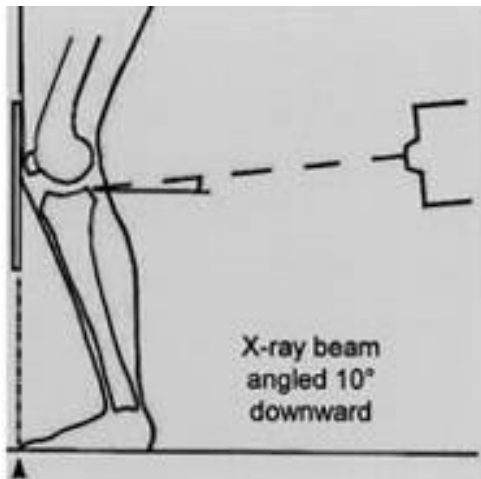
14. T-Spine

- AP, Lateral, Swimmers

15. C-Spine OA Series

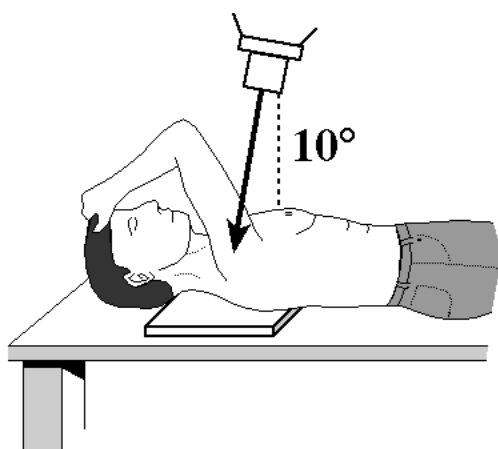
- AP C3-C7 (Note: no odontoid view required)
- Lateral with swimmers if required
- Both oblique views

Additional Information: Views



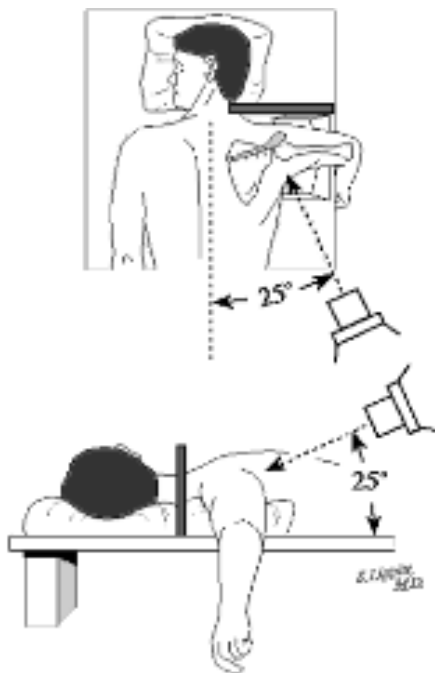
Fixed flexion PA view (20° - 30° of knee flexion)

The patient's feet are placed in 10 degrees of internal rotation with the toes touching against the vertical table. The knees are then flexed until the anterior surface of the knees and thighs are leaning against the table. The x-ray beam is angulated 10 degrees caudal and centered on the knee. Joint space narrowing is best appreciated on this view, as opposed to the Standing AP view, the purpose of which is to provide some information about the alignment of the knee.



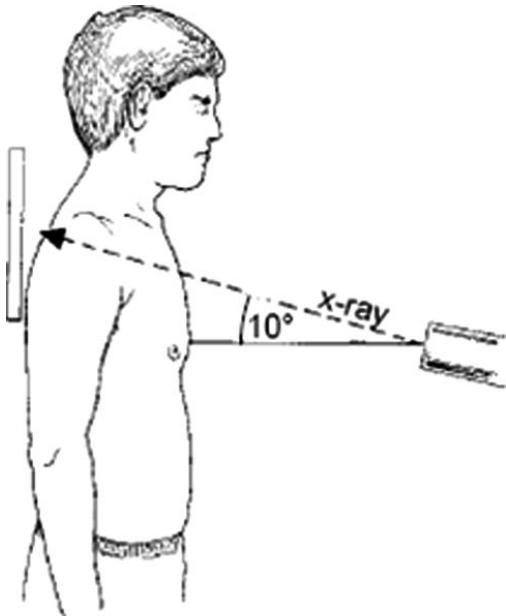
Stryker Notch view

The palm of the hand of the affected shoulder is placed on top of the head, with the fingers directed toward the back of the head. The elbow of the affected shoulder should point straight upward. The x-ray beam tilts 10 degrees toward the head, centered over the coracoid process. This view is optimal for detecting a Hill-Sachs lesion (impaction fracture over the postero-superior humeral head that can occur after anterior dislocation(s)).



West Point Axillary view

The patient is placed prone on the x-ray table with the involved shoulder on a pad raised 7.5 cm from the top of the table. The head is turned away from the involved side. With the cassette held against the superior aspect of the shoulder, the x-ray beam is centered at the axilla, 25 degrees downward from horizontal and 25 degrees medial. This view is used to demonstrate bony abnormalities of the anterior glenoid rim such as bony Bankart lesions or erosions of the anterior glenoid rim which can occur with recurrent anterior shoulder dislocations.



Zanca View

The patient is upright with the beam directed at the AC joint with 10-15 degree cephalic tilt, using only 50% of the usual voltage penetration. This view is optimal for assessing degenerative change in the AC joint.

Rockwood View

The 30 caudal tilt view of Rockwood is an AP of the shoulder with the beam directed at the AC joint with a 30 degree caudal tilt. This view demonstrates the anterior-inferior projection of an acromial spur, if present. The spur will be seen projecting beyond the anterior edge of the distal clavicle. It is felt to be more clinically useful than the supraspinatus outlet view.

Standing PA 30 Degree Flexion

Feet are internally rotated 10 degrees with toes in line with the edge of the vertical stand. Knees are flexed until the anterior surface touched the upright stand. Beam 10 degrees caudal and centered on the knee. Anterior and posterior edges of the tibial plateau should line up. Optimal for assessing joint space narrowing and knee alignment.

